

Jai Sri Gurudev
Sri Adichunchanagiri Shikshana trust ®

ADICHUNCHANAGIRI INSTITUTE OF MEDICAL SCIENCES
NAGAMANGALA TALUK, MANDYA DIST, B G NAGARA, KARNATAKA 571448



ADVISORS

Dr M G SHIVARAMU
PRINCIPAL,AIMS
DR T MANOHAR
MEDICAL SUPERINTENDENT
AH&RC.

CHIEF EDITOR

Dr BG SAGAR
HOD & PROF OF DEPT OF
ORTHOAEDICS.

EDITORIAL BOARD

Dr ABDUL RAVOOF
Dr K G GUNNAIAH
Dr GOPYANAYAK
Dr MADHUKAR K T
Dr C D DEEPAK
Dr GOPINATH
Dr MAHESH D V
Dr SATEESH GS
Dr HARISH K
Dr LOKESH
Dr VISHWANATH
Dr SHREESHA

MEMBERS

Dr ABHEY WASDEV
Dr AKSHAY BANDARI
Dr CHETHAN B A
Dr HARSH TIWARI
Dr KHALID
Dr SHRUTHIKANTH
Dr CHEEMALA VIKRAM REDDY
Dr MOINUDDIN BASHA
Dr SUSHANT SRIVATSAVA
Dr VENKATESH
Dr ASHWINI KUMAR RAI
Dr DILIP
Dr SABNEET SINGH

ORTHO VISION

News letter of department of orthopaedics

EDITORIAL

With divine blessings of Paramapoojya, Jagadguru
Sri Sri Sri Dr Balagangadaranatha Mahaswamiji and
His Holiness

Jagadguru Sri Sri Sri Dr Nirmalanandanatha Mahaswamiji ,
under the able guidance of our beloved principal Dr M G
Shivaramu and with constant support from Dr TM Manohar,
Medical Superintendent, it is our great pleasure to bring forward
'ORTHO VISION', the news letter from orthopaedics department

ORTHO VISION depicts innovative surgeries , recent trends in
treatment modalities offered in AH&RC, AIMS, BG NAGARA.
It also enlists the academic programmes attended by staff and
post graduates.

I extend a warm welcome to all the six new entrant pg's.
Congratulations to all six pgs who successfully completed ms
orthopaedics, Credit goes to the staff members of orthopaedics.

*Endurance is one of the most difficult disciplines ,but it is to the
one who endures that the final victory comes*

- Buddha

Dr B G SAGAR
PROF & HEAD OF DEPT
ORTHOAEDICS

INTERESTING CASES OPERATED IN THE DEPARTMENT OF ORTHOPAEDICS

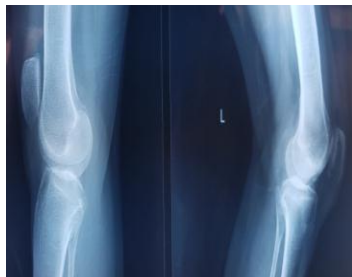1. TOTAL KNEE REPLACEMENT OF LEFT OSTEOARTHRITIC KNEE

DR BG SAGAR, DR MADHUKAR K T, DR SATEESH GS, DR LOKESH, DR MANASH JYOTHI BARUAH, DR ABHEY WASDEV, DR HARSH TIWARI

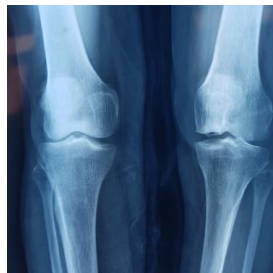
1. A 45 years old lady manual labourer came to the hospital with complaints of left knee pain since three years and also complaints of difficulty in activities of daily living. On examination, patient had tri compartmental osteoarthritis with rupture of medial meniscus

On radiological examination showed there is a defect in the medial condyle of the left femur and decreased joint space.

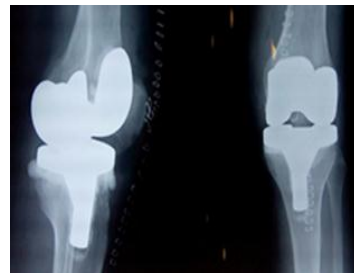Patient underwent total knee replacement .



Pre op

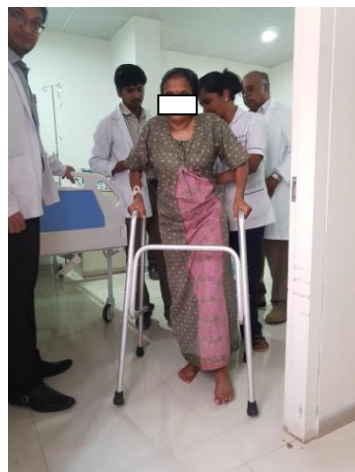
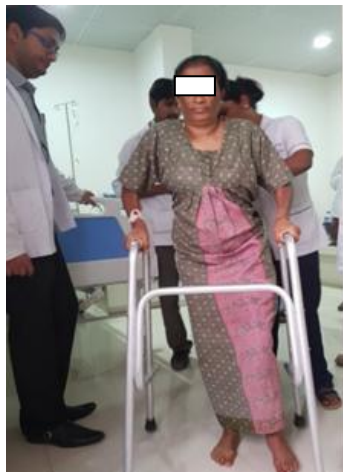
pre op



post op

Post op mobilization



INNOVATIVE METHOD

2. ACROMIOCLAVICULAR JOINT DISLOCATION REPAIRED BY ETHIBOND FIXATION

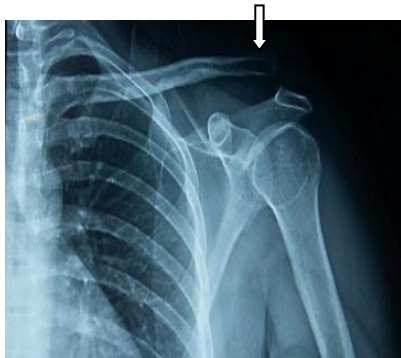DR BG SAGAR, DR GOPYA NAYAK , DR SATEESH, DR LOKESH, DR ABHEY WASDEV , DR VIKRAM REDDY , DR MOINUDDIN BASHA

2. 46yr old male following a fall presented with grade 3 ac joint dislocation of left shoulder . Pain , inability to lift the shoulder prominence of lateral end of the clavicle were chief clinical features

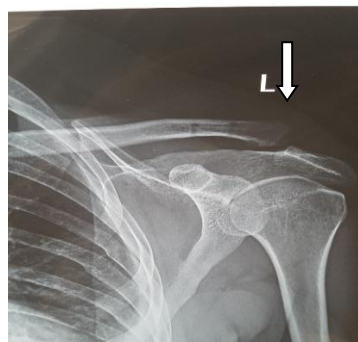On radiological examination : Type 3 Acromioclavicular joint dislocation

Patient was operated for the ac joint dislocation by Ethibond fixation of lateral end of clavicle to the coracoid process hither to literature shows two such series.

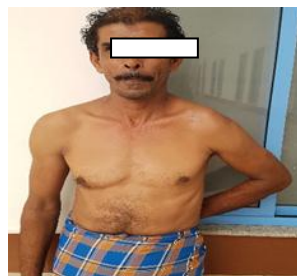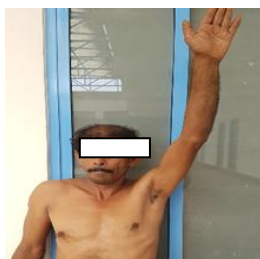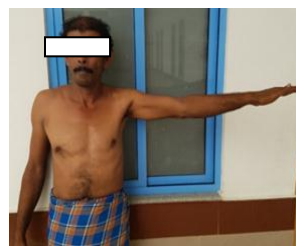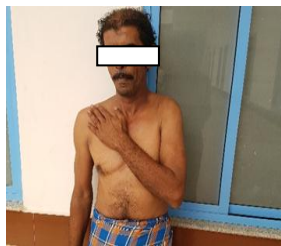PRE OP X RAY



POST OP X RAY



FUNCTIONAL RESULTS

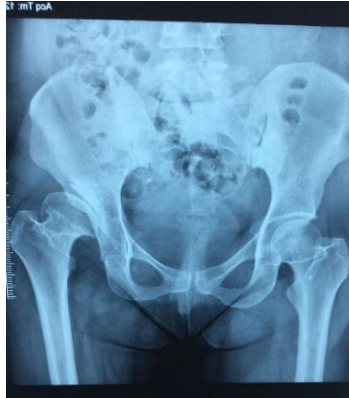

3. TOTAL HIP REPLACEMENT FOR RIGHT OSTEOARTHRITIC HIP

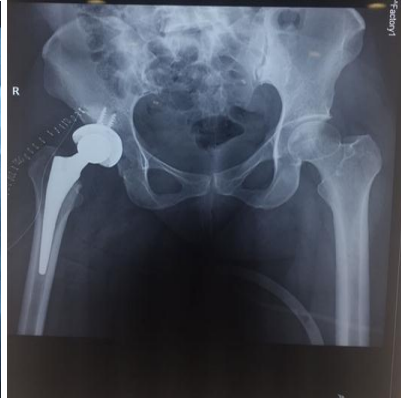DR ABDUL RAVOOF, DR C D DEEPAK , DR MAHESH , DR SHRUTHIKANTH, DR KHALID , DR SUSHANT, DR ASWANI

3. An 31 year female patient with history of pain and limp, difficulty in squatting and sitting cross legged and a short limb. Diagnosed to have arthritic hip with developmental dysplasia of hip was treated by total hip replacement uncemented.

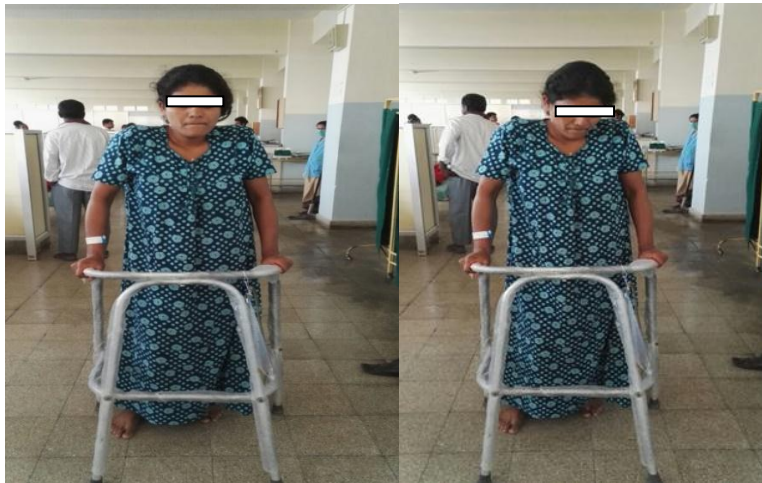PRE OP X RAY



POST OP X RAY



POST OP MOBILIZATION



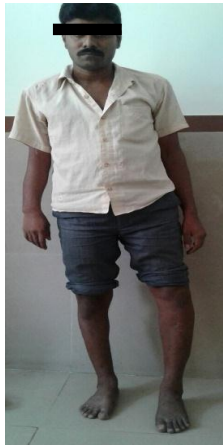4. CORRECTIVE OSTEOTOMY OF VARUS DEFORMITY OF LEFT TIBIA

DR B G SAGAR , DR SATEESH , DR LOKESH , DR ABHEY WASDEV , DR HARSH TIWARI , DR VIKRAM REDDY C , DR MOINUDDIN BASHA K

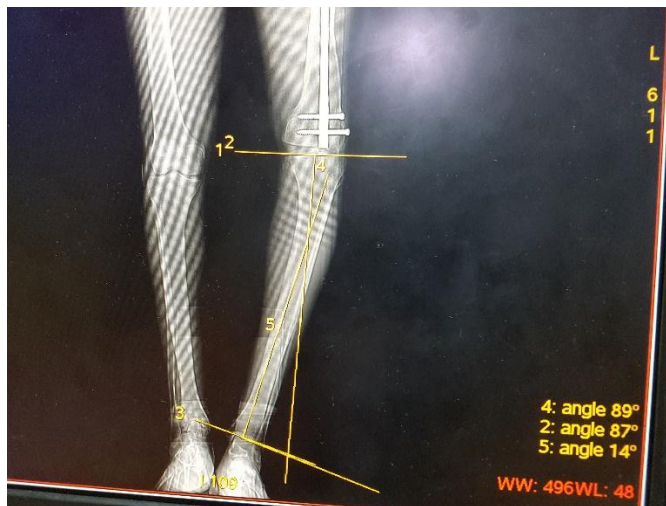35 year old male patient presented with varus deformity of left knee and with lengthening of left lower limb was subjected for corrective osteotomy and fixation



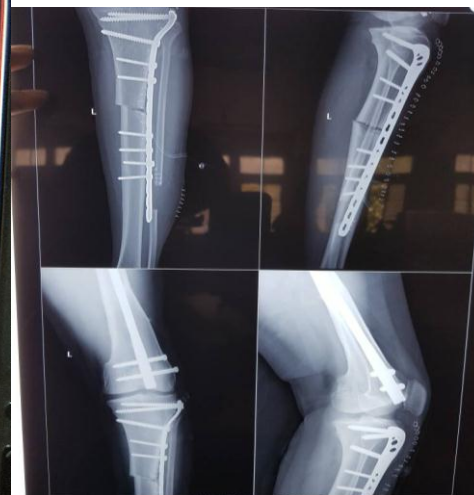PRE OP CLINICAL PICTURE



POST OP CLINICAL PICTURE



PRE OP X RAY



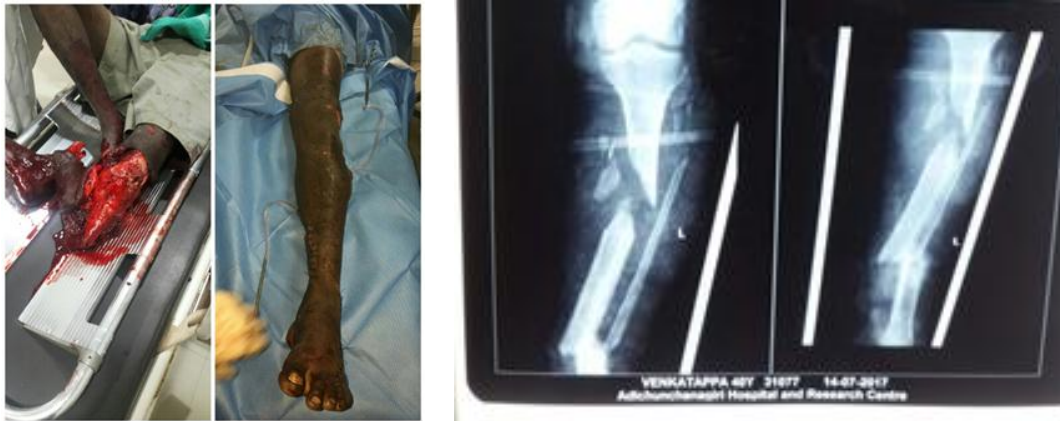POST OP X RAY

5.MANGLED LEFT LEG TREATED BY WOUND DEBRIDEMENT AND ANTBIOTIC COATED INTRAMEDULLARY NAIL FOR TIBIA

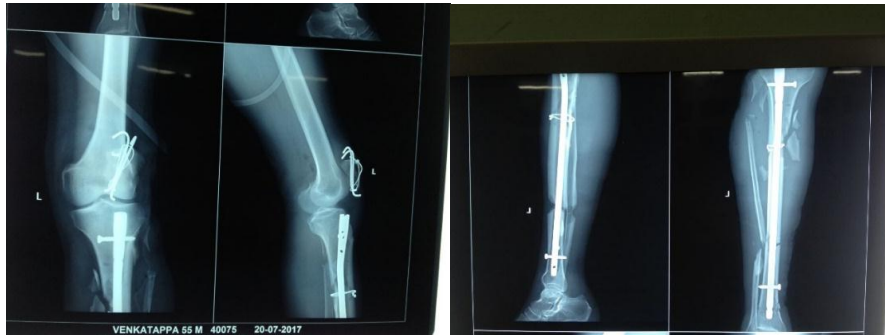DR K G GUNNAIAH , DR HARISH K , DR VISHWANATH C , DR SHRUTHIKANTH, DR MOINUDDIN BASHA K , DR HARSH TIWARI

40 year male patient following road traffic accident sustained type 3 b open fracture both bones leg, open knee joint injury with fracture patella with head injury was salvaged by wound debridement and antibiotic coated intramedullary nail. In anticipation of recovery

PRE OP AND POST OP CLINICAL PICTURE PRE OP XRAY



POST OP X RAY



RESOURCE PERSON AT STATE AND NATIONAL CONFERENCE

1. Dr B G Sagar gave a guest lecture on 5th feb 2017 at KARNATAKA ORTHOPAEDICS CONFERENCE 2017 held at Hubli.
2. Dr BG Sagar was resource person at national seminar on sports injuries with Dr BM Hegde at Seshadripuram college Bangalore.
3. Dr Abdul Ravoof was chairperson for two sessions on 05th and 6th FEB at KOACON 2017 held at Hubli.



4. Orthopedic department organized one educational stall to impart basic knowledge to the viewers present at **JNANA VIGNANA TANTRAGNANA MELA 2017** held at ADICHUNCHANAGIRI MUTT organized on 20th and 21st of feb 2017.

ACADEMIC PROGRAMMES ATTENDED

STAFF :

Dr Lokesh SR attended Ilizerov workshop at Indore under the aegies of Indian Orthopaedic Association during june 2017.

Dr K T Madhukar Associate proffesor, Dr K Harish Assistant professor underwent Revised basic workshop for medical education for teachers at AIMS from 8th to 10th may 2017.

LIST OF PAPER PRESENTATIONS DONE BY STAFF AND POSTGRADUATES AT KOACON 2017

1. FUNCTIONAL OUTCOME OF PROXIMAL FEMORAL NAILING IN INTERTROCHANTERIC FRACTURES PRESENTED AT KOACON 2017 BY DR SATHEESH G S.
2. SURGICAL OUTCOME OF FRACTURE BOTH BONES FOREARM BY TENS PRESENTED AT KOACON 2017 BY DR VISHWANATH C.
3. STUDY OF SEXUAL DYSFUNCTION IN RHEUMATOID ARTHRITIS IN MEN PRESENTED AT KOACON 2017 BY DR ABHEY WASDEV UNDER THE GUIDANCE OF DR MADHUKAR K T.
4. SURGICAL OUTCOME OF PHILOS IN PROXIMAL HUMERUS FRACTURES IN KOACON 2017 BY DR MANASH JYOTI BARUAH UNDER THE GUIDANCE OF DR BG SAGAR.
5. MANAGEMENT OF PROXIMAL FEMUR FRACTURES WITH PF LCP PRESENTED AT KOACON 2017 DR CHETHAN KUMAR R UNDER THE GUIDANCE OF DR GUNNAIAH KG.
6. STUDY OF PERCUTANEOUS K WIRE FIXATION IN SUPRAPROXYLAR FRACTURE OF HUMERUS IN CHILDREN BY DR AKSHAY BHANDARI UNDER THE GUIDANCE OF DR ABDUL RAVOOF.

LIST OF POSTER PRESENTATIONS DONE BY STAFF AND POST GRADUATES AT KOACON 2017

1. LIPOMA ARBORESCENS OF KNEE BY DR VISHWANATH C.
2. CHONDROBLASTOMA OF PROXIMAL TIBIA BY DR VISHWANATH C.
3. ENDOBUTTON TECHNIQUE INN AC JOINT DISLOCATION BY DR VISHWANATH C.
4. SURGICAL OUTCOME OF PROXIMAL TIBIA FRACTURES BY LCP BY DR VISHWANATH C.
5. SURGICAL OUTCOME DISTAL FEMUR FRACTURE BY DF LCP BY DR VISHWANATH C.
6. USE OF ELECTROCAUTERY IN SKIN INCISION FOR ORTHOPAEDIC PROCEDURES BY DR ABHEY WASDEV UNDER THE GUIDANCE OF DR MADHUKAR K T.
7. GAIANT CELL TUMOUR OF TENDON OF HAND BY DR AKSHAY BHANDARI UNDER THE GUIDANCE OF DR ABDUL RAVOOF.
8. MANAGEMENT OF INFECTED NON UNION WITH VASCULARISED FIBULAR GRAFT BY CHETHAN KUMAR R UNDER THE GUIDANCE OF DR GUNNAIAH KG.
9. RESULTS OF SURGICAL TREATMENT OF NON UNION OF HUMERUS SHAFT FRACTURE WITH DCP AND CANCELLOUS BONE GRAFT BY KRISHNA SAI SUNKOJ UNDER THE GUIDANCE OF DR ABDUL RAVOOF.
10. MANAGEMENT OF CTEV BY PONSETI TECHNIQUE BY DR CHETHAN B A UNDER THE GUIDANCE OF DR ABDUL RAVOOF.
11. OUTCOME OF INTERNAL FIXATION OF TIBIAL PLATEAU FRACTURES BY DR CHETHAN B A UNDER THE GUIDANCE OF DR CD DEEPAK.