



**Patron**



Parampoojya Jagadguru  
Sri Sri Sri  
Dr. Nirmalanandanatha  
Mahaswamiji

**Advisor**

Dr. M. G. Shivaramu

*Principal, A.I.M.S.*

*Dr. T.M. Manohar*

*Medical Superintendent*

**Members**

Dr. Prasanna H.R

Prof And HOD

Dr. B.Ranjit Singh

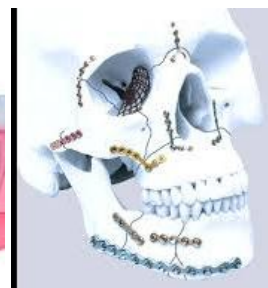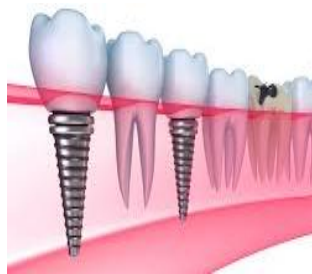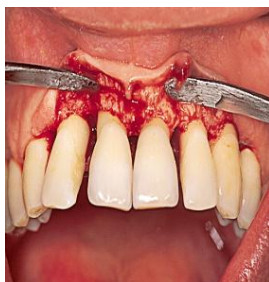Assoc Prof

Dr. Subramanya.G

Asst Prof

Dr. Kavitha .M.N

Snr Resident



# 32 pearls

**Official Newsletter from the Department of Dental.**

**Adichunchanagiri Institute of Medical Sciences**

## **HOD DESK**

With the blessings of Paramapoojya Jagadguru Sri Sri Sri Padmabhushan Dr. Balagangadharanatha Mahaswamiji and his holiness Jagadguru Sri Sri Sri Dr. Nirmalanandanatha Mahaswamiji.

We are coming out with our newsletter 32 **PEARLS** and are very happy to present it to you. I would like to express our gratitude to the Principal, Dr. M. G. Shivaramu for inspiring us with his encouragement.

Now days, Periodontal problems commonly seen in Dental patients, in this issue we throw some light on Periodontal Diseases and its manifestations also treating the same with Bone Grafts.

Department of Dentistry.

Adichunchanagiri Institute of Medical Sciences

# **Bone Grafts in Periodontal Surgeries**

Bone replacement grafts are widely used to promote bone formation and periodontal regeneration. Conventional surgical approaches, such as open flap debridement, provide critical access to evaluate and detoxify root surfaces as well as establish improved periodontal form and architecture; however, these surgical techniques offer only limited potential in restoring or reconstituting component periodontal tissues (Fig. 2.1). Bone grafting materials function, in part, as structural scaffolds and matrices for attachment and proliferation of anchorage-dependent osteoblasts. Multiple classification systems have been used to organize bone replacement grafts, which commonly include source (e.g., allograft), chemical composition (e.g., calcium phosphate) and physical properties (e.g., ceramic). Advances in material sciences, however, have increasingly blurred such boundaries between types of bone replacement grafts (Reynolds et al. 2010)

In general, bone replacement grafts can be categorized into autogenous, allograft, alloplast and xenograft sources.

## **2.1 Autogenous Grafts**

Autogenous bone graft, which is harvested from the patient's own body,

### **2.1.1 Intraoral Autografts**

Intraoral autogenous bone grafts harvested from the maxillary tuberosity, edentulous alveolar areas, healing bony wound, extraction sites and mental and retromolar areas

### **2.1.2 Extraoral Autografts**

Extraoral autografts from iliac cancellous bone and marrow provide a great osteogenic potential, being able to induce cementogenesis, bone regeneration and Sharpey's fibers reattachment

## **2.2 Allografts**

The allografts are obtained from other individuals of the same species but disparate genotype. They include freeze-dried bone allografts (FDBA) and demineralized freeze-dried bone allograft (DFDBA). Bone allograft is the most frequently used alternative to autogenous bone for bone grafting procedures in the USA

### **2.2.1 Freeze-Dried Bone Allografts (FDBA)**

FDBA, which is not demineralized, works primarily through osteoconduction, a process in which the graft does not activate bone growth, but instead acts like a scaffold for the patient's own natural bone to grow onto and within. Over time, the graft is resorbed and replaced by new bone

### **2.2.2 Demineralized Freeze-Dried Bone Allografts (DFDBA)**

Demineralization of a bone allograft exposes bone morphogenetic proteins within the bone matrix. These inductive proteins induce a cascade of events leading to cellular differentiation and the formation of bone through osteoinduction by inducing pluripotent stem cells to differentiate into osteoblasts.

## **2.3 Xenografts**

Xenografts are grafts shared between different species. Currently, there are two available sources of xenografts used as bone replacement grafts in periodontics: bovine bone and natural coral. Both sources, through different processing techniques,

### **2.3.1 Anorganic Bovine-Derived Bone Xenograft (BDX)**

The BDX is a xenograft consisting of deproteinized, sterilized bovine bone with 75–80% porosity and a crystal size of approximately 10 mm in the form of cortical granules (Hürzeler et al. 1997; Piattelli et al. 1999). Regarding both the chemical and physical features, BDX is considered identical to the human bone.

### **2.3.2 Anorganic Porcine-Derived Bone Xenograft**

A natural replicate of autologous bone, OsteoBiol® Gen-Os (TecnoDental, Turin, Italy) conserves the same intimate structures (matrix and porous form) and presents a high osteoconductive activity (Fig. 2.11). It is biocompatible and bioavailable, as recognized by tests made according to the ISO 10993 method conducted at the Università degli Studi di Torino.

## **2.4 Alloplasts (Alloplastic Synthetic Grafts)**

An alloplast is a biocompatible, inorganic synthetic bone grafting material. At present, alloplasts marketed for periodontal regeneration fall into two broad classes: ceramics and polymers. The fate of an alloplastic bone grafting material is dependent primarily on its chemical composition, structure and physical properties

### **2.4.1 Polymethylmethacrylate and Polyhydroxyethylmethacrylate (PMMA-PHEMA) Polymers**

Polymers present some options that the other groups do not. Like many polymers are potential candidates for bone graft substitutes represent different physical, mechanical, and chemical properties. The polymers used today can be loosely divided into natural polymers and synthetic polymers. These, in turn, can be divided further into degradable and nondegradable types

### **2.4.2 Demineralized Dentin Matrix (DDM)**

The organic component of dentin, which accounts for approximately 20% of dentin weight, is mainly type I collagen, a component of bone. Dentin also contains bone morphogenetic proteins (BMPs), which promote the differentiation of mesenchymal stem cells into chondrocytes

### **2.4.3 Hydroxylapatite (HA)**

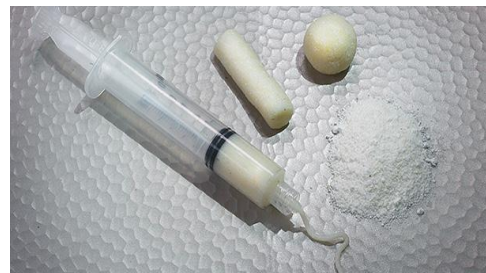Synthetic hydroxyapatite,  $\text{Ca}_{10}(\text{PO}_4)_6(\text{OH})_2$ , has been available for more than 30 years. It is the primary mineral found in bone. Synthetic hydroxyapatite can be found as porous or nonporous and in ceramic or nonceramic forms.

### **2.4.7 Bioactive Glasses (BG)**

Among the different alloplastic materials used in periodontal therapy, hydroxyapatite, calcium phosphates and bioactive glass ceramics share a common factor, which is their capacity to form a carbonated

hydroxyapatite layer on their surfaces once exposed to simulated body fluids or implanted in vivo, hence the concept of “bioactivity.” Since their invention three decades ago by Hench et al. (1971) bioactive glasses have clinically gained wide acceptance in restorative orthopaedics and dentistry.

## Commercially Available Bone Grafts Materials



### 2.6.1 Criteria for Evaluation of Graft Success for Periodontal Regeneration

For any graft material to be considered as a successful regenerative material, it should have clear histological, clinical and radiographic evidence of the following criteria (AlGhamdi et al. 2010a):

1. Biologic acceptability: the graft should not have any side effects or cause any unwanted tissue reaction.
2. Resorbability: the graft should resorb slowly and be replaced by the patient's own bone.
3. Regeneration: the graft should have evidence of regenerative ability with formation of new bone, cementum and periodontal ligament fibers.
4. Defect fill: the graft should have evidence of bone fill.
5. Stability: the outcome of the treatment should be stable at reevaluation visits.

## 2.6.2 Factors Influencing Graft Success

Several studies have investigated the possible sources of variability in the clinical outcomes of bone grafting procedures in periodontal surgery: (1) the patient, (2) the morphology of the defect, (3) the graft material, (4) the surgical procedure and (5) the healing period (Cortellini and Tonetti 2000; AlGhamdi et al. 2010a).

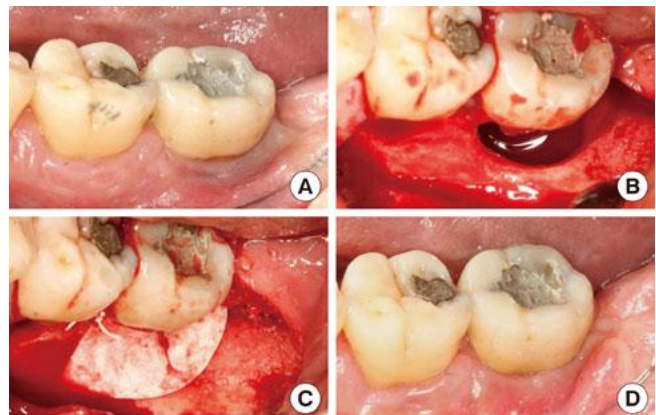
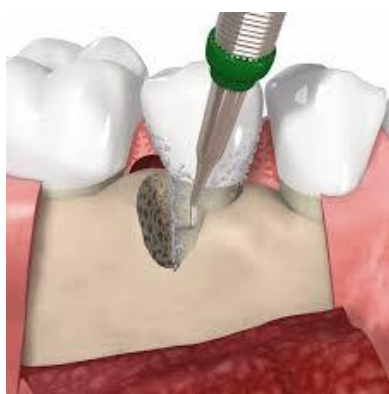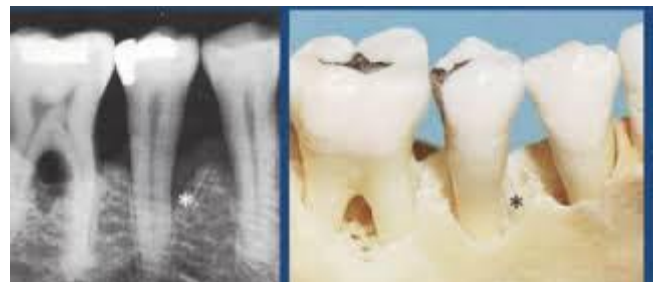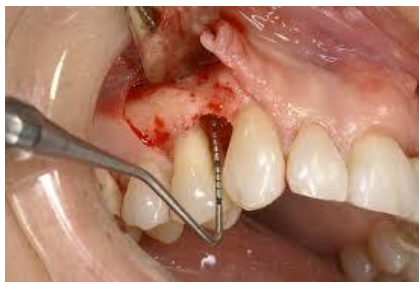### 2.6.2.1 Patient Factors

The scientific literature clearly shows that plaque control (Cortellini et al. 1994), residual periodontal infection, tobacco smoking (Tonetti et al. 1995) and the patient's compliance (Wilson et al. 1984; Wilson et al. 1993b) are important prognostic factors in regenerative periodontal therapy. Other factors include conditions such as diabetes, hyperparathyroidism, thyrotoxicosis, osteomalacia, osteoporosis, Paget's disease and some medications may all affect the healing process (AlGhamdi et al. 2010a).

### 2.6.2.2 The Morphology of the Defect

Among the defect anatomy-associated factors, depth of the intrabony component of the defect and/or probing depth is consistently found to be relevant (Tonetti et al. 1996; Tonetti et al. 1998; Cortellini et al. 2001). The number of residual bony walls defining the defect seems to affect outcomes. Defects with two and three bony walls respond more favorably to treatment than do one-wall defects (Froum et al. 1976; Sepe et al. 1978). Also periodontal regeneration was more successful in deep-narrow defects than in shallow-wide defects (Dragoo and Sullivan 1973a; Froum et al. 1976; Mellonig 1984).

## Periodontal Bone Defects Seen in Patients



### **2.6.2.3 Selection of Graft Material**

When bony reconstruction is presented to the surgeon, many choices must be weighed before the proper graft material is chosen (Kuo et al. 2007). Selection of graft material is guided by:

1. Biologic acceptability
2. Predictability
3. Resorbability
4. Clinical feasibility
5. Minimal operative hazards
6. Minimal postoperative sequelae
7. Patient acceptance (AlGhamdi et al. 2010a and references therein)

A range of 125–1,000 µm is acceptable with 250–750 µm most commonly available for particle size of grafts used in periodontal treatment. A minimal pore size of 100 µm is needed between particles to allow vascularization and bone formation. Particles less than 100 µm in size elicit a macrophage response and are rapidly resorbed with little or no new bone formation (Zaner and Yukna 1984; AlGhamdi et al. 2010a).

### **2.6.2.4 The Surgical Procedure**

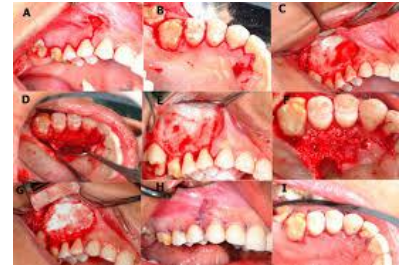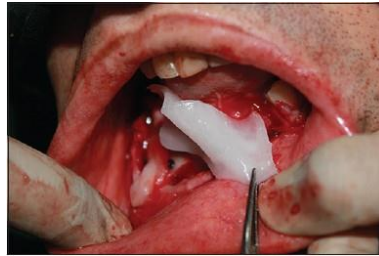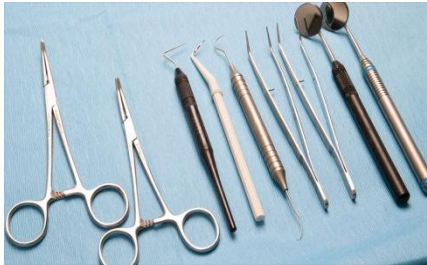The surgical technique for the treatment of periodontal intrabony defects with bone replacement grafts is essentially the same regardless of the type of graft material being used. Incisions are designed to allow for primary closure of flaps to protect the graft site from infection and the graft material from displacement. Intrasulcular incisions are the common choice, with emphasis on preserving interdental tissue. Flaps are reflected full thickness to expose the underlying osseous defects and allow access for thorough debridement of the defects and meticulous root planning (Hanes, 2007). New surgical techniques have been developed to optimize primary closure as well as to minimize the surgical trauma in the reconstructive procedures of periodontal intraosseous defects. Recently, we proposed a minimally invasive procedure, the single-flap approach (SFA), specifically indicated when the defect extension is prevalent on the buccal or oral side. The basic principle of the SFA is the elevation of a flap to access the defect only on one side (buccal or oral), leaving the opposite side intact (Trombelli et al. 2009; Trombelli et al. 2010). Once the defect has been debrided of soft tissue and the tooth root surfaces thoroughly planed to remove all deposits of dental plaque and calculus, the bone replacement graft material is packed into the defect to fill the defect to the level of the remaining alveolar bone (Hanes, 2007). Space maintenance is paramount to bone formation. If the graft material resorbs too rapidly, compared with the time required for bone formation, the site may fill with connective tissue rather than bone (AlGhamdi et al. 2010a). Therefore the space or contour and size of the augmentation should be maintained until the graft has formed enough bone to maintain the space itself (AlGhamdi et al. 2010a; Misch 1999; Polimeni et al. 2006). Absolute graft immobility is paramount to its union to the recipient bone. If pieces of bone graft are mobile, they cannot receive a blood supply, become encapsulated in fibrous tissue and often sequester (AlGhamdi et al. 2010a; Lin et al. 1990). Flaps are closed and sutured for primary closure and complete coverage of the bone replacement graft (Hanes, 2007). Sutures should be removed in 7–10 days.

#### **2.6.2.5 The Postsurgical Healing Period**

Postsurgical care should include twice-daily rinsing with 0.12% chlorhexidine gluconate for 2 weeks and gentle toothbrushing starting 1 week after the surgery. Systemic antibiotics may be prescribed for 7–10 days after the surgical procedure. Patients should be seen at intervals of 1 week, 2 weeks and 4 weeks after



surgery for supragingival plaque removal and then should be placed on a periodontal maintenance schedule at 3-month intervals (Hanes, 2007). Adequate healing time must be provided to allow regeneration of the new bone volume. The amount of time required is variable and depends on local factors such as the number of remaining walls of bone, the amount of autogenous bone in the graft and the size of the defect. Larger grafts, less autogenous bone in the graft and fewer bony walls increase the amount of healing time (AlGhamdi et al. 2010a; Misch and Dietsch 1993; Misch 1999).



## Test Your Oral Health IQ

Does having diabetes increase your risk of dental disease?

- Yes
- No

2 You are more likely to get a cavity if the last time you had a cavity filled was...

- Within the last three years
- More than three years ago

3 Gum disease is associated with...

- Pregnancy
- Heart disease and stroke
- Diabetes
- All of the above

4 Living in a fluoridated community helps reduce my risk for tooth decay.

- Yes
- No
- I don't know. Should I care?

5 Which of the following is a greater risk for cavities?

- Soft drinks/energy drinks
- Cough drops and hard candies
- Sticky foods like taffy and raisins
- Chewing gum
- All of the above

6 Did you know that having a persistently 'dry mouth' can be related to dental disease?

- Yes
- No

7 It is okay to put a baby to bed with a bottle of juice or milk...

- Daily
- Sometimes
- Never

8 What is the role of baby teeth?

- Help babies learn to speak
- Guide permanent teeth into place
- Help the face and jaw develop
- Allow babies to start eating solid food
- Are important even though they eventually fall out
- All of the above

9 The hardest material in the human body is...

- Bone
- Enamel

10 You should brush your teeth...

- Once a week
- Twice a day
- After each meal



## Departmental Activity

Attended Health Camp at and Nagamangala, Hassan, Chikkbalapura



Department participating at Gnana Vignana Tantragnana Mela



Dr. Prasanna H R inaugurated Rotary Cleft Lip and Palate Screening camp held at Hassan and attended Alumni in VS Dental College in Bangalore.





**Dr. Ranjit had attended workshop in USA on IMPLANTS In Dentistry**



**Dr. Subramanya had presented Delegate paper in Karnataka State AOMSI**

**Dr. Subramanya had published article on Gigantic Oral Pyogenic Granuloma of the Oral Cavity in Chettinad Health City Medical Journal.**